

RESEARCH ARTICLE

Open Access



Novel ideas for the comprehensive evaluation of varus knee osteoarthritis: radiological measurements of the morphology of the lateral knee joint

Wenru Ma^{1,2}, Fengkun Wang^{1,2}, Shengnan Sun², Lei Ding³, Lu Wang⁴, Tengbo Yu^{1,5,6*} and Yi Zhang^{1,5,7*}

Abstract

Background The lateral anatomical and morphological characteristics of knees with varus knee osteoarthritis (OA) have not received sufficient attention. This study used several radiological parameters to describe the morphological characteristics of the lateral knee with OA to determine whether there are relationships between varus knee OA and parameters such as lateral plateau widening (LPW), proximal fibula curvature (PFC), and fibula height (FH).

Methods The study retrospectively analyzed 1072 subjects who underwent standard radiography for diagnosing or evaluating symptomatic knee joint disease. The 163 Kellgren and Lawrence (K–L) grades 0 and I knees were categorized into the no-knee-OA group, and the 909 K–L grades II–IV knees were classified into the knee-OA group. Medial proximal tibial angle, joint line convergence angle, hip–knee–ankle angle, LPW, PFC, and FH were measured. T tests and chi-square tests were used to compare each index between the two groups. Binary logistic regression was performed to examine the correlation between indexes and knee OA occurrence. Ordinal logistic analysis, principal component analysis, and multivariable linear regression analysis were performed to examine the correlations between the three lateral parameters and K–L grades and the degree of varus deformity.

Results LPW and PFC were significantly greater and FH was significantly smaller in the knee-OA group than in the no-knee-OA group. LPW, PFC, and FH were correlated with knee OA occurrence. One principal component, named the comprehensive principal component score of varus deformity, was extracted from the three indexes, and the total variance of the principal component interpretation was 76.60%. Ordinal logistics and multivariable linear regression analysis showed that, after adjusting for age and BMI, LPW and PFC were positively correlated with K–L grading and varus deformity. FH was significantly and negatively correlated with K–L grading and varus deformity (all $P < 0.05$).

Conclusions Regular morphological changes take place in the lateral knee with varus OA, including lateral dislocation of the tibial plateau, proximal fibula bending, and upward movement of the fibular head. Changes in LPW, PFC, and FH could enable a more comprehensive assessment of varus knee OA occurrence, severity, and deformity.

Level of evidence Retrospective Study Level III.

*Correspondence:

Tengbo Yu

ybt1970@126.com

Yi Zhang

zhangsports2021@sina.com

Full list of author information is available at the end of the article



© The Author(s) 2023. **Open Access** This article is licensed under a Creative Commons Attribution 4.0 International License, which permits use, sharing, adaptation, distribution and reproduction in any medium or format, as long as you give appropriate credit to the original author(s) and the source, provide a link to the Creative Commons licence, and indicate if changes were made. The images or other third party material in this article are included in the article's Creative Commons licence, unless indicated otherwise in a credit line to the material. If material is not included in the article's Creative Commons licence and your intended use is not permitted by statutory regulation or exceeds the permitted use, you will need to obtain permission directly from the copyright holder. To view a copy of this licence, visit <http://creativecommons.org/licenses/by/4.0/>. The Creative Commons Public Domain Dedication waiver (<http://creativecommons.org/publicdomain/zero/1.0/>) applies to the data made available in this article, unless otherwise stated in a credit line to the data.

Keywords Varus knee osteoarthritis, Genu varus, Radiology, Lateral plateau widening, Proximal fibula curvature, Fibula height

Background

Knee osteoarthritis (OA) is the main cause of chronic pain and disability in middle-aged and older adults and is treated with knee arthroplasty or high tibial osteotomy [1–4]. Varus knee OA caused by varus knee deformity is more common than other OA subtypes [5]; this is the result of ongoing elevated pressure in the medial knee compartment [6].

Radiography is important for diagnosing and evaluating knee diseases. The Kellgren and Lawrence (K–L) grading system is commonly used to evaluate knee joint degeneration based on radiographic findings. The medial proximal tibial angle (MPTA), joint line convergence angle (JLCA), and hip–knee–ankle angle (HKAA) are indexes that are commonly used to assess the degree of lower limb varus deformity.

However, there is little systematic research on the lateral knee with varus OA and few parameters for evaluating degeneration of the lateral knee structures, such as the lateral femoral condyle, lateral tibial plateau, and proximal fibula. Radiological changes in these structures are observed in patients with severe varus knee OA. First, the lateral joint lines of the tibia and femur are misaligned. According to Johannsen et al., lateral plateau widening is useful for evaluating lateral tibial plateau fractures and provides information on how to assess lateral alignment in knee OA [7]. Second, the proximal fibula becomes more curved. Weight-bearing by the fibula, which alters the mechanical distribution of the medial and lateral knee compartment loads, is associated with the pathogenesis of knee OA [8, 9]. Just as a phenomenon, fibula bending has been documented in varus knee OA [10]. Still, there are no comprehensive studies of its relationship with the severity of knee OA or adaptive tibial changes. Its possible role in the assessment of knee OA has also been ignored. Moreover, the fibula head appears to be closer to the lateral tibial plateau. The fibula shifts downward after a proximal fibula osteotomy, which is a new surgery for treating varus knee OA that leads to symptom relief [9], thus suggesting that there is a connection between fibula height and varus knee OA. Systematic clinical studies are needed to clarify these findings for the comprehensive evaluation of varus knee OA.

Therefore, in this novel study, we proposed to focus on radiological changes in the lateral knee joint with varus OA and examined parameters such as lateral plateau widening (LPW), proximal fibula curvature (PFC), and

fibula height (FH). We then investigated the relationship between these parameters and the degeneration and varus deformity of the knee compared with traditional indexes such as K–L grade, MPTA, JLCA, and HKAA.

Methods

Study population

From September 2018 to August 2020, 3127 subjects underwent standard anteroposterior (AP), and lateral radiographs and weight-bearing full-leg AP radiographs to evaluate symptomatic knee joint disease in the Department of Sports Medicine, the Affiliated Hospital of Qingdao University. The inclusion criteria were (1) >45 years of age, (2) no history of knee surgery, and (3) standard AP and lateral and weight-bearing full-leg AP radiography. The exclusion criteria were (1) previous knee trauma or surgery, (2) nondegenerative OA, such as rheumatoid arthritis, Kashin–Beck disease, Dendrolimus OA, hemophilic arthritis, or inflammatory arthritis, (3) congenital deformity or valgus deformity or skeletal dysplasia of the knee, (4) ligament laxity or stiff knee, and (5) tumor or osteopathy of the knee joint. Ultimately, the study enrolled 1072 knees [376 males, 696 females; mean subject age 66.84 (range 46–83) years; mean body mass index (BMI) 26.98 (range 19.43–37.05) kg/m²]. Of the subjects, 909 had different degrees of OA, and the other 163 were healthy. The 2055 excluded knees had a valgus deformity, skeletal dysplasia, rheumatoid arthritis, incomplete radiological data, poor image quality, or lower limb trauma or surgery history.

Radiological measurements

In order to evaluate symptomatic knee joint disease, X-ray examinations, including standard AP and lateral radiographs of the knee and weight-bearing full-leg AP radiographs, were performed in all subjects. The measurements were made independently by one radiologist with 4 years of experience in postprocessing procedures and by a second radiologist with 2 years of experience in orthopedic radiology using the picture archiving and communication system. The patient's position was adjusted so that the toes were straight ahead, with the feet separated sufficiently for balance, and the patient's weight equally distributed on the feet. The radiographic severity of knee OA was assessed with the Kellgren and Lawrence (K–L) grading system [11, 12]. Knees of K–L grades 0 and I were categorized as no-knee OA, and

knees of K–L grades II–IV were categorized as knee OA [13].

Parameters were measured on standard weight-bearing full-leg AP radiographs as shown in Fig. 1. MPTA was measured as the angle between the tibial plateau and the mechanical axis of the tibia. JLCA was measured as the angle between the line connecting the distal femur and proximal tibial articular surfaces on AP radiographs. Intra-articular varus deformity due to the narrowing of the medial joint space often manifests as a positive JLCA value. HKAA was measured as the angle between the mechanical axes of the femur and tibia. Lateral plateau widening (LPW) was measured as the distance between the lateral line along the lateral margin of the distal femoral condyle and the line along the lateral-most aspect of the proximal tibia, both of which are perpendicular to the horizontal plane. Proximal fibula curvature (PFC) was defined as the degree of curvature of the proximal fibula. Fibula is S-shaped and artificially divided into upper, middle, and lower segments. As can be seen in Fig. 1A, point A represents the center of the fibular head (the center point of the line at the widest position of the fibular head), point B represents the distal point of the

middle segment of the fibula, and point C is the center point of the fibula shaft where was of the maximum curvature between point A and point B. Vertical line h was from point C to line c. Lengths of line a, line b, line c, and line h were measured, respectively. PFC was measured as the reciprocal of the radius of the proximal fibula circumcircle using the formula below. Fibula height (FH) was measured as the shortest distance from the tibial plateau to the base of the fibular styloid process on plain radiographs.

Formula for PFC

The radius (r) of the circumcircle of triangle ABC is $\frac{abc}{4S}$ (S is the area of triangle ABC). The curvature of the circumcircle is $\frac{1}{r}$ (Fig. 1).

$$\text{So, PFC} = \frac{1}{r} = \frac{4S}{abc} = \frac{2h}{ab}$$

Statistical analysis

The Kolmogorov–Smirnov normality test was used before the statistical analyses to determine whether to

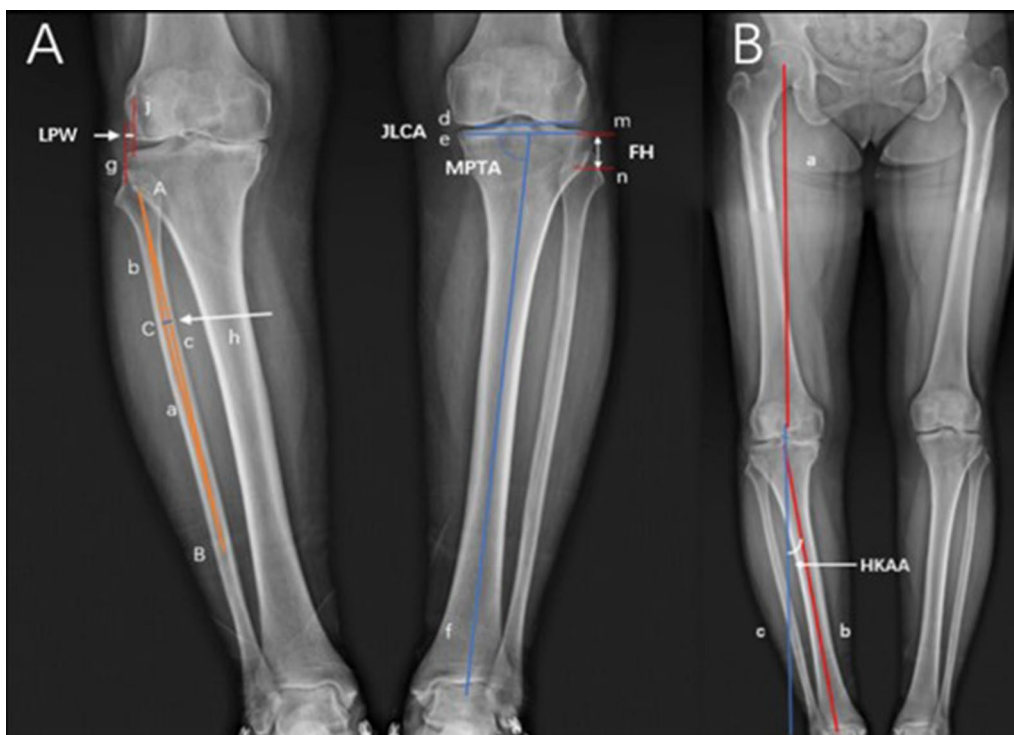


Fig. 1 Schematic diagram of the imaging measurement methods. **A** MPTA was measured as the angle between line e and line f; JLCA was measured as the angle between line d and line e; FH was measured as the shortest distance between line m and line n; LPW was measured as the shortest distance between line g (line along the lateral-most aspect of the proximal tibia) and line j (lateral margin of the distal femoral condyle); PFC was measured as the reciprocal of the radius of the proximal fibula circumcircle, lengths of line a, line b, line c, and line h were measured, respectively. **B** HKAA was measured as the angle between the line b and line c, and line c is the extension of line a

use a parametric test. Continuous variables conforming to the normal distribution were expressed as the mean and standard deviation, and a *t* test was performed to compare radiological measurements between the no-knee-OA and knee-OA groups. Categorical variables were expressed as frequencies (%), and the groups were compared with the chi-square test. Binary logistic regression was performed to determine independent risk factors for knee OA. Kendall's tau-b correlation analysis was performed to compare the radiological parameters and K-L grades, and Pearson's correlation analysis was performed to compare the radiological parameters and MPTA, JLCA, and HKAA. The absolute correlation coefficient (*r*) was used to indicate very strong ($r=0.80-1.00$), strong ($r=0.60-0.79$), moderate ($r=0.40-0.59$), weak ($r=0.20-0.39$), and no ($r<0.20$) correlations. If it was also significantly correlated with MPTA, JLCA, and HKAA, principal component analysis was used to calculate the comprehensive principal component score of varus deformity, which was used to comprehensively evaluate the degree of varus knee deformity by reducing the dimensions of the original data. Odds ratios (ORs) were calculated using ordinal logistic regression to determine whether the radiological parameters were associated with K-L grades, and multivariable linear regression was used for comparison with the comprehensive principal component score of varus deformity. Intra- and interclass correlation coefficients (ICCs) with 95% confidence intervals (CIs) were used to assess intra- and inter-rater variability. $ICC>0.75$ was considered to represent excellent agreement. All statistical evaluations were performed using PASW Statistics (25.0, SPSS, Chicago, IL, USA). A *P*-value <0.05 was considered to be statistically significant.

Results

Basic information

A total of 1072 participants were included in this study and underwent standard radiography. A total of 909 subjects suffering from different degrees of OA, and the other 163 were normal and healthy. Good-to-excellent intraobserver and interobserver variability was achieved for all measurements; the data are presented in Table 1.

All indexes comparison between knee OA and no-knee OA

Table 2 shows each index measured and compared between the knee OA (K-L grades II-IV) and no-knee OA groups (K-L grades 0-I). Significant differences were found in age, BMI, MPTA, JLCA, HKAA, LPW, PFC, and FH (all $P<0.05$) but not in sex ($P=0.110$) between the two groups.

Table 1 Intra- and inter-reliabilities of imaging measurement indexes

	First vs. second assessment by 1 examiner		Assessment by examiner 1 vs. examiner 2	
	ICC	95% CI	ICC	95% CI
MPTA	0.928	0.913-0.940	0.902	0.891-0.919
JLCA	0.920	0.911-0.939	0.878	0.860-0.903
HKAA	0.933	0.916-0.967	0.917	0.899-0.926
LPW	0.925	0.919-0.933	0.873	0.844-0.912
PFC	0.919	0.912-0.928	0.847	0.825-0.880
FH	0.938	0.922-0.953	0.889	0.861-0.920

MPTA medial proximal tibial angle, JLCA joint line convergence angle, HKAA hip-knee-ankle angle, LPW lateral plateau widening, PFC proximal fibula curvature, FH fibular head height, ICC intra- or interclass correlation coefficient, CI confidence interval

Correlations between lateral parameters and knee OA occurrence

To evaluate the influence of lateral parameters on knee OA occurrence, LPW, PFC, and FH were taken into account. Binary logistic regression analysis showed that after adjusting for age and BMI, significant correlations were found between LPW, PFC, FH, and knee OA occurrence ($P<0.05$) (Table 3).

Correlations between lateral parameters and knee OA severity and varus deformity

Kendall's tau-b and Pearson's correlation analysis showed that LPW, PFC, and FH had significant correlations with each conventional OA parameter ($P<0.05$) (Figs. 2, 3, 4).

Results of correlation analysis among LPW, PFC, and FH showed that there are correlations among the three lateral parameters, with $r=0.353$ (LPW and PFC), -0.451 (LPW and FH), and -0.384 (PFC and FH), respectively, all $P<0.001$. Pairwise correlations between MPTA, JLCA, and HKAA were significant, with $r=-0.455$ (MPTA and JLCA), -0.737 (MPTA and HKAA), and 0.742 (JLCA and HKAA), respectively, all $P<0.001$. Therefore, principal component analysis was performed. A total of 1 principal component, named the comprehensive principal component score of varus deformity, was extracted from the three indexes, and the total variance of the principal component interpretation was 76.60%, indicating adequacy and representativeness.

The results of ordinal logistics regression analysis showed that after adjusting for age and BMI, LPW and PFC were positively correlated with K-L grading, and FH was significantly and negatively correlated with K-L grading (Table 4). Multivariable linear regression analysis showed that after adjusting for age and BMI, LPW and

Table 2 Comparison between groups

	Knee OA group	No-knee OA group	t/ χ^2 value	P value
Age	67.82 ± 6.31	61.42 ± 8.35	-8.992	< 0.001
Sex				
Male	300 (0.33)	77 (0.47)	1.626	n.s
Female	609 (0.67)	86 (0.53)		
BMI (kg/m ²)	27.18 ± 3.27	25.81 ± 2.62	-5.721	< 0.001
LPW (mm)	5.1 ± 2.1	1.9 ± 1.1	-28.562	< 0.001
PFC (10 ⁻⁵ × mm ⁻¹)	16.1 ± 9.9	5.3 ± 2.8	-26.386	< 0.001
FH (mm)	17.5 ± 2.3	21.8 ± 1.6	28.866	< 0.001
MPTA (°)	84.28 ± 2.69	87.41 ± 1.41	21.210	< 0.001
JLCA (°)	5.95 ± 2.63	0.88 ± 0.45	-52.073	< 0.001
HKAA (°)	9.95 ± 4.89	2.51 ± 1.55	-35.439	< 0.001

OA osteoarthritis, BMI body mass index, LPW lateral plateau widening, PFC proximal fibula curvature, FH fibular head height, MPTA medial proximal tibial angle, JLCA joint line convergence angle, HKAA hip-knee-ankle angle; n.s., P > 0.05

Table 3 Logistic regression analysis of risk factors for knee OA occurrence

	B	SE	P value	OR (95%CI)
Age	0.141	0.024	< 0.001	1.15 (1.10–1.21)
Sex			n.s	
LPW	0.844	0.151	< 0.001	2.33 (1.73–3.13)
PFC	0.308	0.049	< 0.001	1.36 (1.24–1.50)
FH	-0.718	0.099	< 0.001	0.49 (0.40–0.59)

OA osteoarthritis, BMI body mass index, LPW lateral plateau widening, PFC proximal fibula curvature, FH fibular head height, B regression coefficient, SE standard error of regression coefficient, OR odds ratio, CI confidential interval, n.s., P > 0.05

PFC were positively correlated with varus deformity, and FH was significantly and negatively correlated with varus deformity (all P < 0.05) (Table 5).

Discussion

In radiographic studies of knee OA, the lateral anatomical and morphological characteristics of the knee have not received sufficient attention, possibly because lateral degeneration seems to be less severe than medial degeneration or because the fibula is not the main component of the knee joint and bears little axial load [13, 14]. However, lateral structures play a role in the degeneration of the knee; the bony support of the fibula has a role in the mechanism of knee OA, which was named the “non-uniform settlement” theory [8, 9]. The soft tissues of the lateral knee are important for knee stability. The posterolateral ligament complex, including the lateral collateral, arch, and popliteal ligaments and popliteal tendon, prevents varus deformity and abnormal external rotation of the tibia [15–20]. These morphological abnormalities are obvious in knee OA [21–23]. Therefore, lateral knee

structures deserve more attention, especially in knees with OA.

To our knowledge, this is the first large study to describe the anatomy and morphology of the lateral knee joint and its association with knee OA. Our results showed that in varus knee OA, the anatomical position and morphology of the lateral knee on radiography changed, and may be determined by changes in the mechanical environment of the lower limbs. These changes were accompanied by changes in K–L grade and the morphological indexes MPTA, JLCA, and HKAA, suggesting that LPW and PFC are significantly and positively correlated with the severity of knee OA and genu varus deformity, while FH is negatively correlated.

LPW is sensitive to knee alignment and indicates the relative location and distance between the proximal lateral tibia and lateral femoral condyle by drawing two lines perpendicular to the medial tibial articular surface [24]. Studies have used LPW to evaluate lateral tibial plateau fractures [24]. We found that LPW can also be used to evaluate the degree of lateral alignment in patients with varus knee OA. The average LPW of a healthy knee is 0.02 ± 2.03 mm, so the lateral aspect of the tibial plateau should be collinear with the lateral femoral condyle [24, 25]. Here, almost all LPW measurements in patients with varus knee OA were positive and were closely related to knee OA occurrence, progression, and varus deformity. According to past study reports, the relative outward displacement of the tibial plateau, a positive LPW, represents an increase in stress in the lateral structure [26], which also affects the state of the fibula head [24, 25]. In addition to the view of joint mismatch in the previous studies, we believe that the tibial intercondylar ridge is closer to the lateral femoral condyle, resulting in increased structural pressure of the lateral knee structures. So, a change

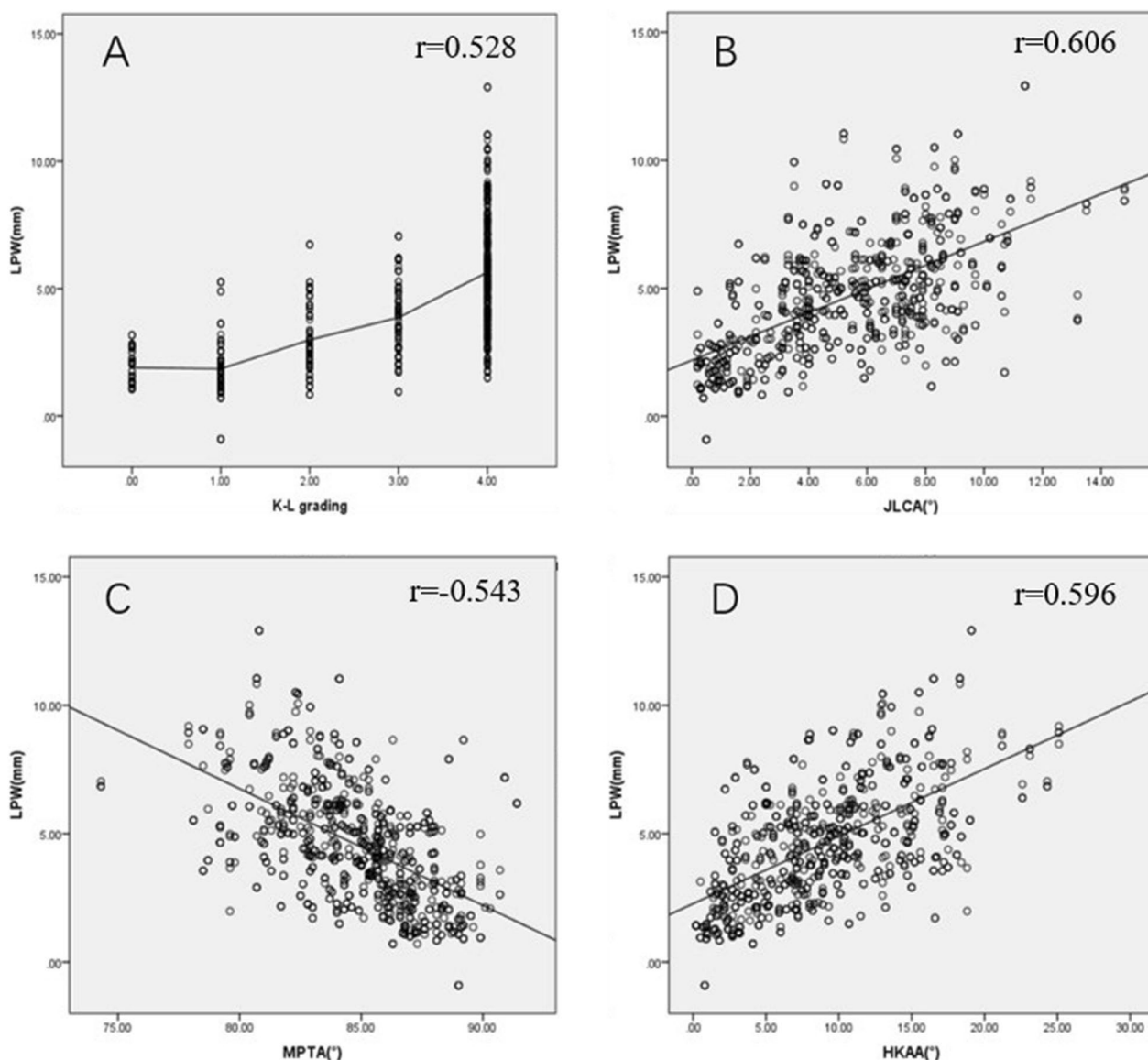


Fig. 2 Results of correlation analysis. LPW, lateral plateau widening; K-L grading, Kellgren and Lawrence grading; JLCA, joint line convergence angle; MPTA, medial proximal tibial angle; HKAA, hip-knee-ankle angle. **A** The higher the K-L grade, the bigger the LPW; **B** LPW is positively correlated with JLCA; **C** LPW is negatively correlated with MPTA; **D** LPW is positively correlated with HKAA. All $P < 0.001$

in LPW might be the direct cause of increased stress in the lateral structures when varus OA occurs.

The PFC describes morphological variation in the fibula instead of the fibular shaft axis. Kuroda et al. defined the fibular shaft axis as the line connecting the center of the fibular head to the center of the lateral malleolus; it is commonly used as a radiographic landmark for planning total knee arthroplasty [27]. PFC was defined as the angle formed by the proximal medullary cavity central line and the middle medullary cavity central line of the fibula in a previous study with inaccuracy because

the curvature was described by angle [10]. PFC reflects the degree of bending in the proximal fibula with a new definition used here and calculated by the formula mentioned above, and it is proportional to lateral stress. We found that the PFC was significantly correlated with JLCA, MPTA, and HKAA and directly or indirectly affected the lateral structure of the knee, similar to the fibular shaft axis on plain radiographs. Xie et al. reported that the medial cortex of the proximal fibular shaft is a reliable landmark for the mechanical axis of the tibia in positive HKAA knee OA [28]. Our results suggest that

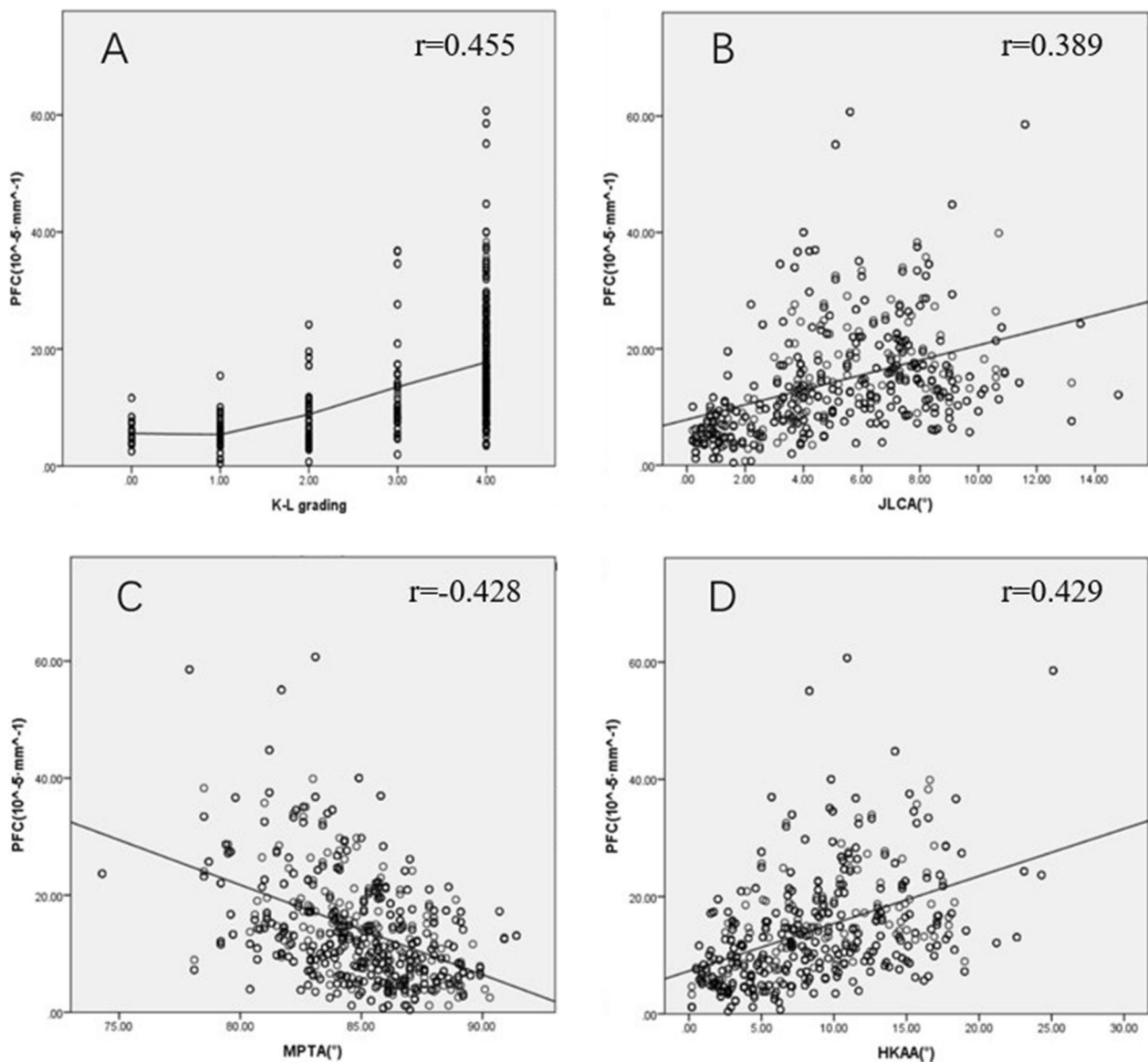


Fig. 3 Results of correlation analysis. PFC, proximal fibula curvature; K-L grading, Kellgren and Lawrence grading; JLCA, joint line convergence angle; MPTA, medial proximal tibial angle; HKAA, hip-knee-ankle angle. **A** The higher the K-L grade, the bigger the PFC; **B** PFC is positively correlated with JLCA; **C** PFC is negatively correlated with MPTA; **D** PFC is positively correlated with HKAA. All $P < 0.001$

the validity of the fibular shaft axis may be an objective manifestation of changes in mechanical stress on the fibula, which are influenced by changes in the load along the tibial mechanical axis. This suggests that changes in the mechanical axis of lower limbs contribute to changes in both the tibia and fibula, rather than just one in isolation. Because of the proximal tibiofibular joint structure, little dislocation of the fibula occurs in the presence of genu varus deformity. The lateral muscles and tendons place more tractive force on the lateral fibular cortex, as demonstrated by the periosteal reaction in the lateral cortex

of the fibula on OA radiographs. This mechanism may be the main cause of fibula bending.

We proposed to use the parameter FH to describe the height of the fibular head relative to the tibial plateau. The decrease in FH observed in knee OA indicates that the fibula shifts upward relative to the tibial plateau. FH was significantly and negatively correlated with K-L grade (odds ratio [OR]=0.53), JLCA, and HKAA, and was significantly and positively correlated with MPTA. According to Preuschoff, the vertical force acting on the fibula is a tensile force, not a compressive force. This

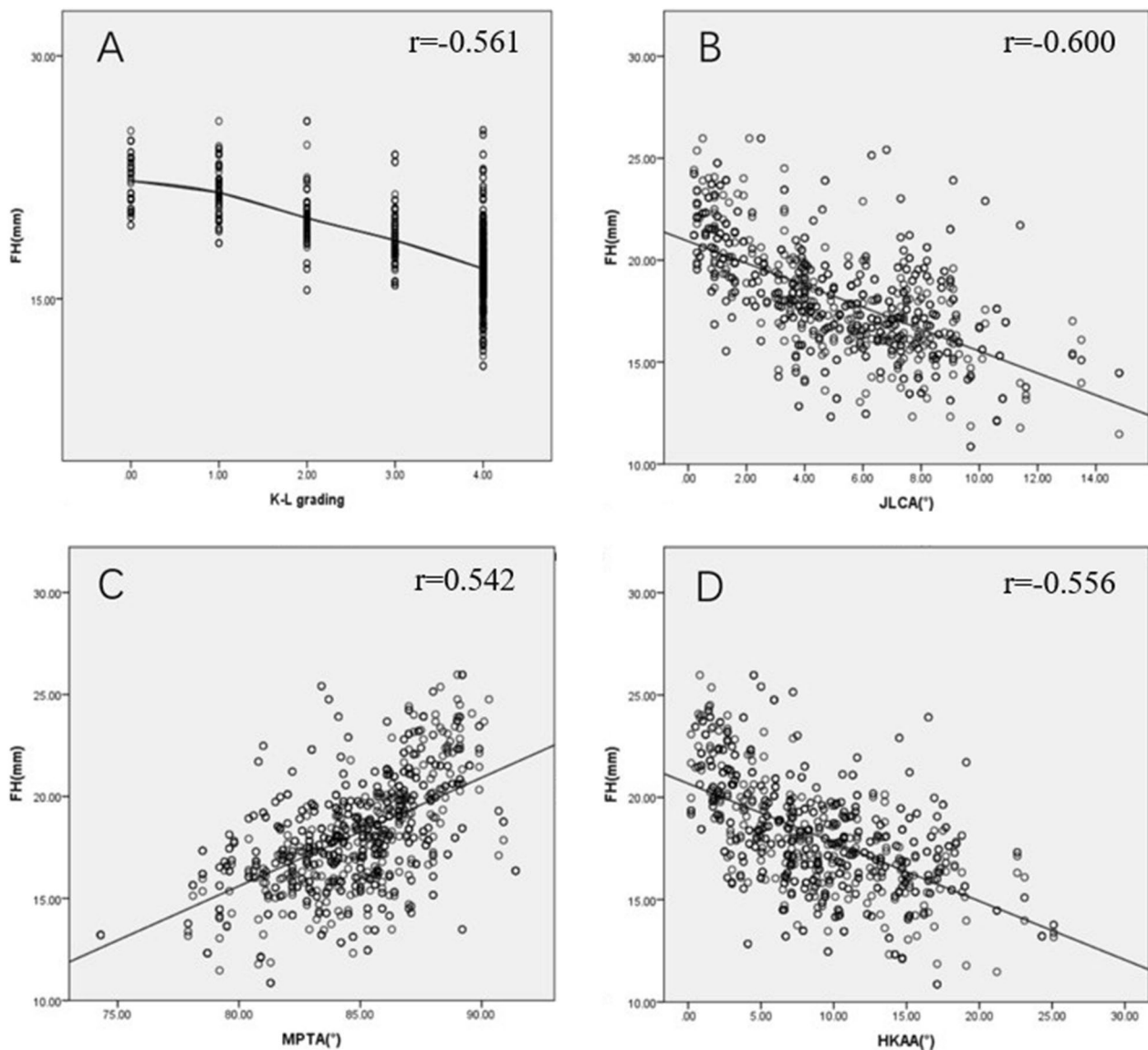


Fig. 4 Results of correlation analysis. FH, fibular head height; K-L grading, Kellgren and Lawrence grading; JLCA, joint line convergence angle; MPTA, medial proximal tibial angle; HKAA, hip–knee–ankle angle. **A** The higher the K–L grade, the smaller the FH; **B** FH is negatively correlated with JLCA; **C** FH is positively correlated with MPTA; **D** FH is negatively correlated with HKAA. All $P < 0.001$

Table 4 Ordinal logistics regression analysis of K–L grading

	B	SE	P value	OR (95% CI)
Age	0.108	0.012	< 0.001	1.11 (1.09–1.14)
BMI	0.010	0.028	n.s	1.01 (0.96–1.07)
LPW	0.656	0.057	< 0.001	1.93 (1.72–2.16)
PFC	0.125	0.015	< 0.001	1.13 (1.10–1.17)
FH	-0.632	0.044	< 0.001	0.53 (0.49–0.58)

K–L grading Kellgren and Lawrence grading, LPW lateral plateau widening, PFC proximal fibula curvature, FH fibular head height, B regression coefficient, SE standard error of regression coefficient, OR odds ratio, CI confidential interval, n.s., $P > 0.05$

explains the upward movement of the fibula, although it may also result from settling of the lateral tibial plateau, which should be examined in further studies. LaPrade et al. reported that the fibula head affects the force and proximal tibiofibular articulation via the lateral structures, which transmit and distribute the lateral tensile force generated by limb gravity [29]. Theoretically, the function of the posterolateral ligament complex declines as the fibula shifts upward because it relaxes. Simultaneously, the pressure in the medial knee compartment increases [30, 31], which eventually leads to knee degeneration, such as hyperosteo-geny and osteosclerosis [32].

Table 5 Multivariable linear regression analysis of comprehensive principal component score of varus deformity

	Unstandardized coefficient	Standardized coefficient B	t value	P value	B 95% CI	
	0.154		0.469	0.639	-0.490	0.798
Age	0.016	0.110	5.423	<0.001	0.010	0.021
BMI	0.004	0.014	0.681	n.s	-0.008	0.017
LPW	0.174	0.403	16.558	<0.001	0.153	0.194
PFC	0.017	0.174	7.918	<0.001	0.013	0.022
FH	-0.131	-0.356	-15.221	<0.001	-0.148	-0.114

BMI body mass index, LPW lateral plateau widening, PFC proximal fibula curvature, FH fibular head height, B regression coefficient, CI confidential interval; n.s., $P > 0.05$

Consequently, the decreased FH could be a lateral knee characteristic that aggravates knee OA.

In addition, our results showed that there are statistical correlations among the three imaging indexes about lateral knee structure. It is suggested that the three morphological changes in the lateral knee have synchronicity and consistent indicative significance. Referring to the characteristics of medial indexes about varus knee joint degeneration, we collectively refer to the three lateral indexes as indexes about lateral knee joint degeneration. Commonly, degeneration is associated with increased pressure in the knee compartments, which involve medial and lateral compartments to varying degrees. The consistent indicative significance of the three lateral morphological changes could be reflected by that they were all related to increased pressure on the lateral structures of the knee. Theoretically, the abnormal increased pressure, the settlement of the tibial plateau, the O-shaped deformed lower limb and the increased traction on the fibula head together lead to a long-term bowl-like pressure state of the fibula, which is regarded as the important mechanism for the fibula shifts upward and the bending of the fibula shaft. As described above, an increased LPW indicates an abnormal increase in pressure on the lateral knee compartment. And, the mechanical environment changes caused by these morphological deformities could in turn lead to the aggravation of degeneration.

The interaction between the fibula and tibia may be involved in adaptive changes in the pathogenesis and progression of knee OA, but this is currently unclear. Lacking superior or inferior bony support, the fibula cannot bear gravity directly but anchors to the tibia via the interosseous membrane and proximal and distal tibi-fibular joints. Considering the structural proximity of the tibia and fibula, factors influencing fibula changes in OA might include increased traction of the lateral knee joint and proximal tibia varus deformation on the fibula, which would gradually increase in prominence with knee OA severity. There is extensive evidence to show that changes in the tibia's anatomical and mechanical features

affect the fibula's position and morphology, especially the fibula position [33–35]. The traditional view is that the main function of the fibula is to dissipate and transmit axial loads during weight-bearing, but recent studies have suggested mechanical self-adaptability of the fibula in OA and the influence of the fibula on the tibial load in turn [36–38]. Therefore, changes in the anatomical and morphological characteristics of the fibula and tibia in OA may help to explain the mechanical interaction between the tibia and fibula during knee OA.

Generally, varus knee OA involves medial knee compartments first and gradually involves the lateral. When medial and lateral knee compartments are all involved which is the end-stage osteoarthritis, total knee arthroplasty is the major surgical treatment. However, noninvasive treatments, intraarticular puncture and injection, high tibial osteotomy, and unilateral knee arthroplasty are also common ways for knee OA with different severity grades; therefore, it is not enough for traditional indicators to focus only on the degeneration of the medial structures according to the requirements of targeted minimally invasive treatment; and the lack of a method for evaluating degeneration of the lateral knee structures may be an important reason for the lack of standard indications for total knee arthroplasty. Based on the evaluation of the lateral knee degeneration, the classification of knee OA severity will also be more accurate and effective, and this is worthy of further studies. Consequently, although our study focuses on the three morphological changes in the lateral knee, it could provide ideas for enabling a more comprehensive assessment of varus knee OA and for a more reasonable treatment for the knee OA by regarding the medial and lateral compartments as separate structures. Furthermore, it will provide us with ideas for predicting the risk of total knee arthroplasty.

This study has several limitations. First, this study involved a large-sample radiographic analysis, so biomechanical findings were neglected. Imaging variation in the fibula does not directly reflect mechanical changes around the knee joint. Second, the rotational relationship

between the tibia and fibula cannot be measured using plain radiography of the knee, although this relationship may exist in knee OA. Third, the impact of rotation or flexion of the limbs on the measurements cannot be observed on 2D radiographs.

Conclusion

Regular morphological changes, including lateral dislocation of the tibial plateau, proximal fibula bending, and upward movement of the fibular head, take place in the lateral knee with varus knee OA. Changes in LPW, PFC, and FH are significantly correlated with varus knee OA occurrence, and these parameters will enable a more comprehensive assessment of varus knee OA severity and deformity. Furthermore, these adaptive changes in the lateral knee joint could reflect the mechanical synergism and interaction of the tibia and fibula promoting varus deformity in knee OA.

Abbreviations

OA	Osteoarthritis
LPW	Lateral plateau widening
PFC	Proximal fibula curvature
FH	Fibula height
BMI	Body mass index
K-L grade	Kellgren and Lawrence grade
MPTA	Medial proximal tibial angle
JLCA	Joint line convergence angle
HKAA	Hip-knee-ankle angle
AP	Anteroposterior

Acknowledgements

We appreciate the technical support provided by the Radiology Department of the Affiliated Hospital of Qingdao University.

Author contributions

All authors contributed to the study conception and design. Material preparation, data collection, and analysis were performed by F.W., S.S., and L.D. The first draft of the manuscript was written by W.M., and the necessary corrections and additions to the manuscript were made by S.S. and L.W. Y.Z. gave theoretical guidance. T.Y. and Y.Z. were responsible for the overall direction and review. All authors commented on previous versions of the manuscript. All authors read and approved the final manuscript.

Funding

This study was funded by the National Natural Science Foundation of China (No. 31802022).

Availability of data and materials

The final dataset will be available from the corresponding author.

Declarations

Ethics approval and consent to participate

Approval was obtained from the research ethics committee of the Affiliated Hospital of Qingdao University (Ethics number: QFYWZLL 26089). Verbal informed consent was obtained from all individual participants included in the study, and this was approved by the ethics committee.

Consent for publication

Not applicable.

Competing interests

The authors declare that they have no conflict of interest.

Author details

¹Department of Sports Medicine, Affiliated Hospital of Qingdao University, 59 Haier Road, Laoshan District, Qingdao 266000, Shandong Province, China. ²Department of Clinical Medicine, Qingdao University, Qingdao, Shandong Province, China. ³Department of Quality Management Evaluation, Affiliated Hospital of Qingdao University, Qingdao, Shandong Province, China. ⁴Department of Education and Training, Affiliated Hospital of Qingdao University, Qingdao, Shandong Province, China. ⁵Department of Orthopedics, Affiliated Hospital of Qingdao University, Qingdao, Shandong Province, China. ⁶Institute of Sports Medicine and Rehabilitation, Qingdao University, Qingdao, Shandong Province, China. ⁷Shandong Institute of Traumatic Orthopedics, Qingdao, Shandong Province, China.

Received: 2 April 2022 Accepted: 6 March 2023

Published online: 13 March 2023

References

- Billings A, Scott DF, Camargo MP, Hofmann AA. High tibial osteotomy with a calibrated osteotomy guide, rigid internal fixation, and early motion: long-term follow-up. *J Bone Joint Surg Am*. 2000;82(1):70–9. <https://doi.org/10.2106/00004623-200001000-00009>.
- Preshaw RM. High tibial osteotomy technique for knee osteoarthritis. *CMAJ: Can Med Assoc J = journal de l'Association medicale canadienne* 2018;190(43):E1287. <https://doi.org/10.1503/cmaj.70285>.
- Seil R. In high tibial osteotomy, closing and opening wedges did not differ for clinical outcomes at up to two years. *J Bone Joint Surg Am*. 2018;100(10):882.
- Vincent KR, Conrad BP, Fregly BJ, Vincent HK. The pathophysiology of osteoarthritis: a mechanical perspective on the knee joint. *PM&R*. 2012;4(5 Suppl):S3–9.
- Felson DT, Lawrence RC, Dieppe PA, Hirsch R, Helmick CG, Jordan JM, et al. Osteoarthritis: new insights. Part 1: the disease and its risk factors. *Ann Intern Med*. 2000;133(8):635–46.
- Nie Y, Ma J, Huang Z, Xu B, Tang S, Shen B, et al. Upper partial fibulectomy improves knee biomechanics and function and decreases knee pain of osteoarthritis: a pilot and biomechanical study. *J Biomech*. 2018;71:22–9.
- Johannsen AM, Cook AM, Gardner MJ, Bishop JA. Defining the width of the normal tibial plateau relative to the distal femur: Critical normative data for identifying pathologic widening in tibial plateau fractures. *Clin Anat (New York, NY)*. 2018;31(5):688–92. <https://doi.org/10.1002/ca.23196>.
- Dong T, Chen W, Zhang F, Yin B, Tian Y, Zhang Y. Radiographic measures of settlement phenomenon in patients with medial compartment knee osteoarthritis. *Clin Rheumatol*. 2016;35(6):1573–8.
- Qin D, Chen W, Wang J, Lv H, Ma W, Dong T, et al. Mechanism and influencing factors of proximal fibular osteotomy for treatment of medial compartment knee osteoarthritis: a prospective study. *J Int Med Res*. 2018;46(8):3114–23.
- Wang J, Lv HZ, Chen W, Fan MK, Li M, Zhang YZ. Anatomical adaptation of fibula and its mechanism of proximal partial fibulectomy associated with medial compartment knee osteoarthritis. *Orthop Surg*. 2019;11(2):204–11. <https://doi.org/10.1111/os.12437>.
- Kellgren JH, Lawrence JS. Radiological assessment of osteoarthrosis. *Ann Rheum Dis*. 1957;16(4):494–502.
- Petersson IF, Boegård T, Saxne T, Silman AJ, Svensson B. Radiographic osteoarthritis of the knee classified by the Ahlbäck and Kellgren & Lawrence systems for the tibiofemoral joint in people aged 35–54 years with chronic knee pain. *Ann Rheum Dis*. 1997;56(8):493–6.
- Espegueira-Mendes JD, da Silva MV. Anatomy of the proximal tibiofibular joint. *Knee Surg Sports Traumatol Arthrosc*. 2006;14(3):241–9. <https://doi.org/10.1007/s00167-005-0684-z>.
- Helminen HJ. Sports, loading of cartilage, osteoarthritis and its prevention. *Scand J Med Sci Sports*. 2009;19(2):143–5. <https://doi.org/10.1111/j.1600-0838.2008.00881.x>.

15. LaPrade RF, Tso A, Wentorf FA. Force measurements on the fibular collateral ligament, popliteofibular ligament, and popliteus tendon to applied loads. *Am J Sports Med.* 2004;32(7):1695–701.
16. Markolf KL, Graves BR, Sigward SM, Jackson SR, McAllister DR. Effects of posterolateral reconstructions on external tibial rotation and forces in a posterior cruciate ligament graft. *J Bone Joint Surg Am.* 2007;89(11):2351–8.
17. Marshall JL, Girgis FG, Zelko RR. The biceps femoris tendon and its functional significance. *J Bone Joint Surg Am.* 1972;54(7):1444–50.
18. Thauinat M, Pioeger C, Chatellard R, Conteduca J, Khaleel A, Sonnery-Cottet B. The arcuate ligament revisited: role of the posterolateral structures in providing static stability in the knee joint. *Knee Surg Sports Traumatol Arthrosc.* 2014;22(9):2121–7.
19. Vap AR, Schon JM, Moatshe G, Cruz RS, Brady AW, Dornan GJ, et al. The role of the peripheral passive rotation stabilizers of the knee with intact collateral and cruciate ligaments: a biomechanical study. *Orthop J Sports Med.* 2017;5(5):2325967117708190.
20. Veltri DM, Deng XH, Torzilli PA, Warren RF, Maynard MJ. The role of the cruciate and posterolateral ligaments in stability of the knee: a biomechanical study. *Am J Sports Med.* 1995;23(4):436–43.
21. Pagnano MW, Hanssen AD. Varus tibial joint line obliquity: a potential cause of femoral component malrotation. *Clin Orthop Relat Res.* 2001;392:68–74.
22. Yagi T, Sasaki T. Tibial torsion in patients with medial-type osteoarthritic knee. *Clin Orthop Relat Res.* 1986;213:177–82.
23. Matsui Y, Kadoya Y, Uehara K, Kobayashi A, Takaoka K. Rotational deformity in varus osteoarthritis of the knee: analysis with computed tomography. *Clin Orthop Relat Res.* 2005;433:147–51.
24. Johannsen AM, Cook AM, Gardner MJ, Bishop JA. Defining the width of the normal tibial plateau relative to the distal femur: critical normative data for identifying pathologic widening in tibial plateau fractures. *Clin Anat.* 2018;31(5):688–92. <https://doi.org/10.1002/ca.23196>.
25. Durakbasa MO, Kose O, Ermis MN, Demirtas A, Gunday S, Islam C. Measurement of lateral plateau depression and lateral plateau widening in a Schatzker type II fracture can predict a lateral meniscal injury. *Knee Surg Sports Traumatol Arthrosc.* 2013;21(9):2141–6. <https://doi.org/10.1007/s00167-012-2195-z>.
26. Kumar A, Passey J, Khan R, Arora R, Kumar S, Chouhan D, et al. Defining the “mediolateral widening of tibial plateau” as a guide for reduction in tibial plateau fractures: an Indian perspective. *J Clin Orthopaed Trauma.* 2020;11:566–70. <https://doi.org/10.1016/j.jcot.2019.06.006>.
27. Kuroda Y, Ishida K, Matsumoto T, Sasaki H, Matsuzaki T, Oka S, et al. Fibular axes are not a reliable landmark for tibial mechanical axes of osteoarthritic knees that underwent total knee arthroplasty. *Knee Surg Sports Traumatol Arthrosc.* 2015;23(11):3362–7. <https://doi.org/10.1007/s00167-014-3170-7>.
28. Xie K, Han X, Jiang X, Wang L, Ai S, Yu Z, et al. The fibular shaft axis and medial cortex of the proximal fibula are reliable landmarks for the mechanical axis of the tibia in patients with knee osteoarthritis. *Knee.* 2019;26(6):1386–94. <https://doi.org/10.1016/j.knee.2019.08.007>.
29. Kruckeberg BM, Cinque ME, Moatshe G, Marchetti D, DePhillipo NN, Chahla J, et al. Proximal tibiofibular joint instability and treatment approaches: a systematic review of the literature. *Arthrosc: J Arthrosc Relat Surg.* 2017;33(9):1743–51. <https://doi.org/10.1016/j.arthro.2017.03.027>.
30. Kenaway M, Lioudakis E, Krettek C, Ostermeier S, Horn T, Hankemeier S. Effect of the lower limb rotational alignment on tibiofemoral contact pressure. *Knee Surg Sports Traumatol Arthrosc.* 2011;19(11):1851–9.
31. Yazdi H, Mallakzadeh M, Sadat Farshidfar S, Givehchian B, Daneshparvar H, Behensky H. The effect of tibial rotation on knee medial and lateral compartment contact pressure. *Knee Surg Sports Traumatol Arthrosc.* 2016;24(1):79–83.
32. Thorp LE, Wimmer MA, Block JA, Moisiu KC, Shott S, Goker B, et al. Bone mineral density in the proximal tibia varies as a function of static alignment and knee adduction angular momentum in individuals with medial knee osteoarthritis. *Bone.* 2006;39(5):1116–22.
33. Thienpont E, Schwab PE, Cornu O, Bellemans J, Victor J. Bone morphotypes of the varus and valgus knee. *Arch Orthop Trauma Surg.* 2017;137(3):393–400. <https://doi.org/10.1007/s00402-017-2626-x>.
34. Kornilov N, Kulyaba T, Petukhov A, Ignatenko V, Thienpont E. Computer navigation helps achieving appropriate gap balancing and restoration of alignment in total knee arthroplasty for fixed valgus knee osteoarthritis irrespective of the surgical approach. *Acta Orthop Belg.* 2015;81(4):673–81.
35. Thiippanna RK, Kumar MN. Lateralization of femoral entry point to improve the coronal alignment during total knee arthroplasty in patients with bowed femur. *J Arthroplasty.* 2016;31(9):1943–8. <https://doi.org/10.1016/j.arthro.2016.02.057>.
36. Kim TW, Lee SH, Lee JY, Lee YS. Effect of fibular height and lateral tibial condylar geometry on lateral cortical hinge fracture in open wedge high tibial osteotomy. *Arthrosc: J Arthrosc Relat Surg.* 2019;35(6):1713–20. <https://doi.org/10.1016/j.arthro.2019.01.044>.
37. Baldini T, Roberts J, Hao J, Hunt K, Dayton M, Hogan C. Medial compartment decompression by proximal fibular osteotomy: a biomechanical cadaver study. *Orthopedics.* 2018;41(4):e496–501. <https://doi.org/10.3928/01477447-20180424-05>.
38. Utomo DN, Mahyudin F, Wijaya AM, Widhiyanto L. Proximal fibula osteotomy as an alternative to TKA and HTO in late-stage varus type of knee osteoarthritis. *J Orthop.* 2018;15(3):858–61. <https://doi.org/10.1016/j.jor.2018.08.014>.

Publisher's Note

Springer Nature remains neutral with regard to jurisdictional claims in published maps and institutional affiliations.

Ready to submit your research? Choose BMC and benefit from:

- fast, convenient online submission
- thorough peer review by experienced researchers in your field
- rapid publication on acceptance
- support for research data, including large and complex data types
- gold Open Access which fosters wider collaboration and increased citations
- maximum visibility for your research: over 100M website views per year

At BMC, research is always in progress.

Learn more biomedcentral.com/submissions

